

# TREATMENT OF BRACHIAL ARTERIAL PSEUDOANEURYSM AND THE IMPORTANCE OF EARLY DIAGNOSIS WITH DOPPLER ULTRASONOGRAPHY


## ABSTRACT


With the increased use of endovascular procedures, a rise in the number of cases of pseudoaneurysms has been seen. They have a low incidence, being its etiology traumatic or iatrogenic. Potential complications are edema, pain, hemorrhage and ischemia of the affected limb, which can even lead to loss of the fingers.


We report a clinical case of a patient with brachial artery pseudoaneurysm after coronary angioplasty, which was resolved with Doppler ultrasound- guided puncture with thrombin injection.

**Keywords:** pseudoaneurysm, brachial artery, thrombin injection.

## Authors

Yamil N. Ponce<sup>1</sup>, 

Sandra P. Raznovich<sup>2</sup>, 

Paola Belsito Malaspina<sup>3</sup> 

<sup>1</sup> Cardiovascular Surgeon; Hospital G. A. Dr. Cosme Argerich, CABA. Professor of Medicine. Specialist in Phlebology (UBA).

<sup>2</sup> General Surgeon (MAAC), Hospital G. A. Dr. Teodoro Álvarez, CABA. Phlebology and Lymphology (UCA).

<sup>3</sup> Cardiovascular Surgeon; Hospital G. A. Dr. Cosme Argerich, CABA. Deputy Director of the Specialization Program in Cardiovascular Surgery, Argerich Site, School of Medicine of the University of Buenos Aires. Specialist in Phlebology and Lymphology (UCA).

## Correspondence:

Dr. Yamil Ponce

e-mail: [yamilponce@hotmail.com](mailto:yamilponce@hotmail.com)

## INTRODUCTION

Pseudoaneurysms or false arterial aneurisms are defined as cavities in which a rupture of the vascular wall permits blood extravasation, which leads to pulsatile hematoma<sup>(1)</sup>. Said hematoma is surrounded by a pseudo-sac formed by adjoining tissues, which means that this pseudo-sac is not formed by elements of the vascular wall. Its etiology can be infectious, traumatic<sup>(1)</sup> or iatrogenic. The latter has seen an increase given the advances in interventional medicine with increased use of diagnostic and therapeutic methods.

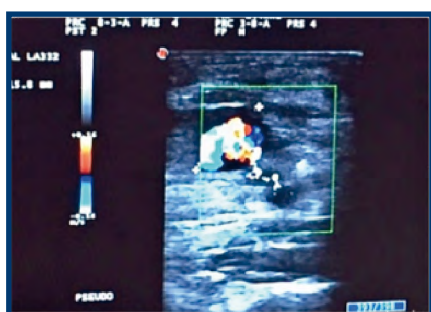An incidence of post-puncture complications has been described, ranging from 0.2 to 7%<sup>(2)</sup>, whereas other studies report up to 9%. Pseudoaneurysm accounts for 1.5% of post-angiography complications and up to 6% of post therapeutic procedures complications<sup>(3)</sup>.

It is well known that brachial artery pseudoaneurysms have a low incidence, although it has increased in recent years as a result of the greater use of upper limbs in endovascular procedures. Given their potential complications, i.e. hemorrhage, edema, pain, limb ischemia, pseudoaneurysms must be treated promptly.

We report a clinical case of brachial artery pseudoaneurysm diagnosed by doppler ultrasound and treated with ultrasound-guided thrombin injection. The study allowed for early diagnosis and satisfactory treatment, reducing morbidity as it is a method that does not require the use of nephrotoxic contrast agents or radiation, allowing for real time evaluation and reducing hospitalization time and related costs.

## CASE REPORT

Male, 69 year-old patient, with a history of coronary angioplasty of 7 days of evolution. The approach pathway was the brachial artery of the right upper limb. Ecodoppler was performed, diagnosing brachial artery pseudoaneurysm (Figure 1). It was decided to attempt to compress it on two occasions, not obtaining the expected result.



**FIGURE 1.** Pseudoaneurysm. Measurement of the cavity, neck diameter and length and jet speed.

The ecodoppler revealed a patent brachial artery, with preserved flow pattern and the presence of a 15.8 mm diameter pseudoaneurysm with the typical ying-yang pattern, patent 2.4 mm diameter and 11 mm long neck, with a high-speed and resistance flow pattern.

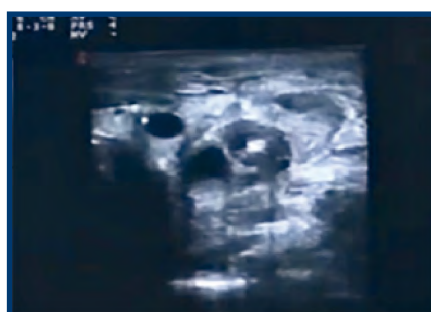Thrombin was injected in the bottom of the sac with the aim of thrombosing, not reaching the neck in order to avoid migration of the product as it might cause arterial thrombosis. Being this a real-time procedure, once thrombosis in the sac was observed it was decided not to continue injecting thrombin although the neck remained patent, since as there is no cavity to receive the blood, the neck would thrombose. In order to prove that this was the case, the patient was seen at 24 hours for ecodoppler control (Figure 2). Neck and pseudoaneurysm sac thrombosis was observed. Even so, the patient was seen for a second control with ecodoppler 7 days after the procedure, evidencing complete exclusion of the pseudoaneurysm.

## COMMENTS

Brachial artery pseudoaneurysms are infrequent but, given their potential complications, they are considered a vascular emergency.

Treatments range from a watch and wait approach, manual compression, endovascular procedures to conventional surgery. Endovascular procedures with stent placement use nephrotoxic iodine agents that also imply a high cost, whereas conventional surgery requires anesthesia and hospitalization.

Thrombin injection has proven to be effective and does not require iodine contrast agents or anesthetics, does not expose the patient to radiation, can be administered in an outpatient procedure with few hours of stay in the medical center and allows for arterial hemodynamic control of the treated limb. This method also makes it possible to prove effectiveness of the procedure and arterial patency in real time and, finally, it also reduces treatment costs<sup>(3)</sup>.



**FIGURE 2.** Obliteration of the sac, control 24 hours after the procedure.

Vascular ecodoppler is a fundamental diagnostic tool (94% to 97% sensitivity)<sup>(4)</sup>. It permits evaluation of the lesion features (number of cavities, dimension, presence of thrombi, internal septa), the relation with neighboring structures, study of the arterial tree (walls and flows) and the presence of thrombi in vascular structures. With this method it is possible to establish differential diagnosis, namely: true aneurysm, hematoma, arteriovenous fistula, lipoma, neoplasia or abscesses.

On the other hand, it is a low cost, reproducible method that can be performed on the bed side, not using radiation or nephrotoxic contrast media. It has been proven that ultrasound-guided percutaneous thrombin injection is safe and efficacious<sup>(5,6)</sup>.

It must be noted that when an endovascular procedure is required, it is necessary to consider that there are predisposing factors for the development of an aneurysm, including anticoagulation, age older than 60, use of larger diameter catheters, obesity, non-effective compression in the puncture site or technical errors during the procedure.

We conclude that ecodoppler is a fundamental tool in the diagnosis and treatment of vascular procedures.

### Conflicts of interest

The authors have no disclosures to declare.

### REFERENCES

1. Otero Reyes M., García Lizame M., Mussenden O., y col; Pseudoaneurisma postraumático humeral. *Rev Cubana Angiol Cir Vasc.* 2014;15.
2. González D., Hasbún S., Tapia R., y col; Tratamiento de pseudoaneurisma iatrogénico con compresión ecoguiada; *Rev. Chil. Cir.*; vol. 70 Santiago ago. 2018
3. dos Santos Nogueira A., Gonzalez Salgado C., Belloni dos Santos Nogueira F., y col; Pseudoaneurismas: Cuándo y Cómo Tratarlos; *Arq. Bras Cardiol: imagen cardiovasc.* 2013; 26(4):289-307.
4. Mendaro E., de Candido L.; Manejo del Pseudoaneurisma femoral; 284-289.
5. Norese M., Chen H., Paulo Neto T., y col; Pseudoaneurisma humeral secundario a punción arterial inadvertida; *Rev. Argent. Cir.*; 113(4):487-491, dic. 2021.
6. Jargiello T., Sobstyl J., Światłowski L., y col; Ultrasound-guided thrombin injection in the management of pseudoaneurysm after percutaneous arterial access. *J Ultrason* 2018;18(73):85-89.